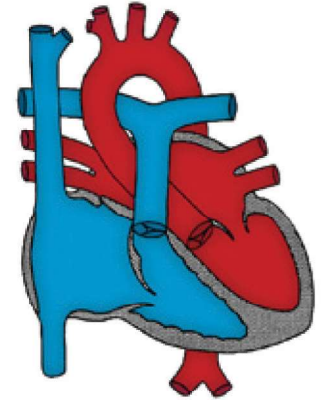
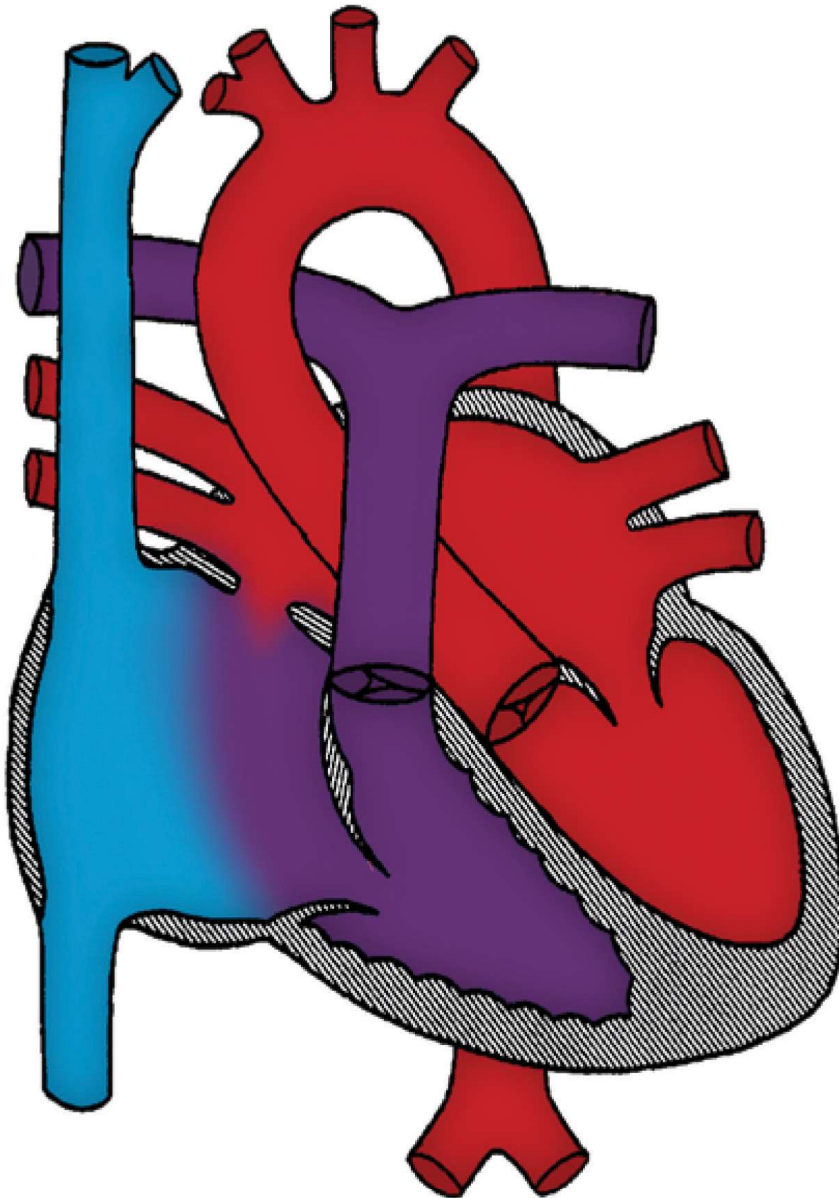




COMMUNICATION INTERAURICULAIRE (OSTIUM SECUNDUM)



Cœur normal